

ASSESSMENT OF UNILOCLAR OVARIAN CYSTS IN PREMENOPAUSAL WOMEN USING TRANSVAGINAL ULTRASONOGRAPHY, ASPIRATION CYTOLOGY AND ESTRADIOL CONTENT

*Mohamed El-Said Ghanem, M.D**, *El-Said Abdel-Hady, PhD, MRCOG**, *Rafat Abdel-Fattah, M.D**, *Kamal Anwar, M.D**, *Mohamed Nezar, MD* Ikkal Abo-Hashem, M.D***, *Ahmed Gebreel, M.Sc**,

*Departments of Obstetrics & Gynaecology, and **Clinical Pathology, Mansoura University Teaching Hospital, Mansoura, EGYPT.

ABSTRACT

Objectives: To assess the diagnostic accuracy of transvaginal ultrasound, aspiration cytology and estradiol content alone and in triad in the discrimination between functional and nonfunctional unilocular ovarian cysts in premenopausal women.

Methods: Premenopausal women (n=18) with unilocular ovarian cysts undergoing laparoscopy were recruited. Intracystic fluid was obtained by needle aspiration and subjected to cytology and estradiol content. The cyst wall that was removed during laparoscopy/laparotomy was subjected to histopathology as a gold standard. Cysts were classified into functional or non-functional according to the results of transvaginal ultrasonography, cytology and estradiol content.

Results: The diagnostic accuracy of transvaginal sonography was 61 %, cytology 72 % and estradiol content 83 % in differentiating unilocular ovarian cysts into functional and non-functional. When the triad was used in combination, the diagnostic accuracy was increased to 94 %.

Conclusion: Aspiration of unilocular ovarian cysts based on assessment by transvaginal ultrasound alone may not be sufficient. The addition of cytology and estradiol content increased the diagnostic accuracy. This triad can reduce the number of unnecessary laparotomies especially in young subfertile women.

Key words: Ovarian cysts, ultrasonography, cytology and estradiol content.

INTRODUCTION

The management of unilocular ovarian cysts represents a challenge to the gynecologist. Multimodal methods improve the results of preoperative discrimination between benign and malignant cysts than a single modality ⁽¹⁾.

Follicular cysts, corpus luteum cysts and theca lutein cysts comprise the category of functional ovarian cysts, which require no surgical management ⁽²⁾. Transvaginal ultrasound is used to determine the origin of the cyst, the size, echogenicity and the internal architecture ⁽³⁾. The use of reproducible sono-morphologic criteria in

Corresponding author : El-Said Abdel-Hady, Department of Obstetrics & Gynaecology, Mansoura University Teaching Hospital, Mansoura, EGYPT. e-mail:elsaidhady@yahoo.co.uk.

pre-menopausal women with ovarian cysts has proved to be an efficient tool to reduce the number of unnecessary operations and to evaluate the risk of malignancy (4). However, ultrasound alone may not be conclusive in the differentiation between functional and non-functional cysts and therefore, neoplastic cysts may be overlooked. The use of cytology and the measurement of estradiol level in the intracystic fluid may be of value in this respect (5). The recognition of granulosa cells in the intracystic aspirate allows the diagnosis of functional cysts (6). Occasionally, the distinction between granulosa and epithelial cells may be difficult and estradiol assay in the intracystic fluid along with cytology might produce the final diagnosis (7).

In this study we aimed to assess the diagnostic accuracy of transvaginal ultrasound, cytology and estradiol level in the discrimination between functional and nonfunctional unilocular ovarian cysts in premenopausal women undergoing laparoscopy/laparotomy.

PATIENTS & METHODS

Patient's Selection

Premenopausal women recruited for this study were undergoing laparoscopy/laparotomy at the department of Obstetrics and Gynaecology, Mansoura University Teaching Hospital. Eighteen patients with a diagnosis of unilocular ovarian cyst persisting after 3 months of follow up were selected. Ultrasonic criteria of simple ovarian cysts included size less than 7 cm in diameter, absence of septae, internal echogenecity and with no intracystic papillary growths (See figure 1).

Aspiration of the cysts was carried out during laparoscopy using needle aspiration. The

intracystic fluid obtained was submitted for cytological examination and estradiol level measurement. The cyst wall, removed during laparoscopy/laparotomy, was sent for histological examination.

Cytological examination

The aspirated fluid was centrifuged, spread on a glass slide then fixed by alcohol-ether mixture for at least 30 minutes. Slides were stained using Papanicolaou stain. Functional ovarian cysts were diagnosed when clusters of granulosa cells, whether luteinized or not, were present on preparations of the smear. Non-functional cysts contained epithelial cells, mesothelial-like cells and endometrial cells.

If the preparation contained only red blood cells whether intact or haemolysed, it was considered hemorrhagic and the preparation to be non-informative. When the preparation was acellular, it was also considered non-informative.

Biochemical analysis of the intracystic fluid for estradiol level

Samples from the aspirated fluid were subjected to a direct solid phase enzyme immunoassay for the quantitative measurement of estradiol. Quantitative estradiol content of the sample was done with a cut-off- level of 4000 pg/ml, above which the cyst was considered to be functional (8-10).

Statistical Analysis:

Classification of the cysts into functional or non-functional category was analysed using ultrasonography, estradiol concentration and cytological results. Cysts with acellular or haemorrhagic smears were classified into functional or non-functional according to E₂ content. Accuracy of transvaginal sonography,

cytology and estradiol measurement was determined alone or in combination. Sensitivity, specificity, positive and negative predictive values were assessed with histopathology of the cyst wall as the gold standard. Statistical analysis was done with χ^2 and Yates' corrected χ^2 test.

RESULTS

Ultrasonographic findings:

Transvaginal ultrasound correctly diagnosed 5/6 functional and 6/12 non-functional cysts, when compared with histopathological examination. The sensitivity and specificity of ultrasound were 50% and 83.3% respectively. The overall accuracy of ultrasound was 61.1%.

Cytological findings:

In 2 cases (11.2%) the aspirates were cytologically non-informative because of the absence of diagnostic cells. In another 3 cases (16.1%) the aspirate was hemorrhagic containing only haemolysed RBCs and degenerated cells. In the remaining 13 cases, cytological examination of the aspirate was sufficient to differentiate the cysts into functional or non-functional. This means that cytological examination of the intracystic fluid was able to diagnose 13/18 (72.2%) ovarian cysts in the right functional or non-functional category.

Estradiol content:

Estradiol was available for assay in 17 cases. In 4 cases the estradiol level was higher than 4000 pg/ml denoting functional cysts and the diagnosis was correct as regard histopathology. In 11 cases a correct diagnosis of non-functional cysts was obtained when estradiol level was less than 4000 pg/ml. Estradiol level in two hemorrhagic cysts was also higher than 4000 pg/ml, so they were

classified as functional cysts.

The overall accuracy of E_2 was 88.2%. The 2 acellular smears by cytology were exposed to E_2 assay, which revealed a content of more than 4000 pg/ml in one of them denoting functional cyst. This was proved by histopathology.

The overall accuracy of ultrasound, cytology, estradiol and UCE triad in the diagnosis of functional and non-functional ovarian cysts:

From table (I), it is evident that the diagnostic accuracy was increased from 61% (ultrasound alone) to 72% with (cytology alone). In both cases, there was a significant difference when compared to histopathology. On the other hand, E_2 content (83%) and UCE triad 94.4% were not significantly different when compared to histopathology.

DISCUSSION

Unilocular ovarian cyst is a frequently reported ultrasonic finding in premenopausal women. The aim of clinical management is to optimize the treatment of suspicious cysts while minimizing intervention for cysts likely to resolve spontaneously^(11,12). In this study, only 50% of non-functional ovarian cysts were diagnosed accurately by transvaginal sonography, this low sensitivity was previously reported⁽¹³⁾. A size over 7 cm, internal echoes and intra or extra cystic vegetations seems to be important features of neoplasticity^(14,15) and hence to be non-functional. Five cysts were classified as non-functional because of their large diameter over 7 cm, one of them was proved to be functional by histopathology. Functional ovarian cysts with a size up to 10 cm was also reported by others⁽¹⁵⁾. Transvaginal ultrasound-guided needle aspirations although proposed by many⁽¹⁶⁻¹⁸⁾ as a diagnostic

and therapeutic approach, is opposed by others because of the high recurrence rate ^(19,20) and the theoretical risk of spreading malignancy ^(21,22). By incorporating the appearance of the cyst by transvaginal ultrasonography with cytological examination and estradiol content, this risk could be abolished ^(16,23).

Cytological examination in this study, contributed to the accurate diagnosis of 13/18 cysts. One of the acellular samples was proved by histopathology to be of borderline malignancy, so malignancy could not be excluded by acellular smears, this was also reported by others ⁽²⁴⁾. In this study, two of the hemorrhagic smears were proved by histopathology of the cyst wall to be hemorrhagic corpus luteum and the other one was serous cystadenoma with hemorrhage inside, so hemorrhagic cysts are of no value in the differentiation between functional and non-functional cysts and this has also been previously reported by many authors ^(24,25).

Measurement of estradiol level is important in differentiating functional from non-functional cysts ^(5,8,9). In this study, 80% of functional ovarian cysts had an E₂ content > 4000 pg/ml. False positive results could be explained by puncture of adjacent follicular cyst or due to hyperplasia of ovarian stroma ⁽⁸⁾.

The combination of the triad of ultrasound, cytology and E₂ content, increased the diagnostic accuracy to 94%. This result when interpreted clinically into a diagnostic and therapeutic approach could allow transvaginal ultrasound guided aspiration followed by cytology in combination with E₂ assay as an outpatient management for unilocular ovarian cysts in subfertile women.

CONCLUSION

The triad of ultrasound, cytology and estradiol content can differentiate between functional and non-functional ovarian cysts with high accuracy and without the need for laparotomy especially in premenopausal and subfertile women.

REFERENCES

- 1- Knudsen UB, Tabor A, Mosgaard B, Andersen ES, Kjer JJ, Hahn-Pedersen S, Toftager-Larsen K, Mogensen O. Management of ovarian cysts. *Acta Obstet Gynecol Scand.* 2004 Nov; 83(11):1012-21.
- 2- Grimes DA, Hughes JM. Use of multiphasic oral contraceptives and hospitalization of women with functional ovarian cysts in the United States. *Obstet Gynecol* 1989; 73: 1037-9.
- 3- Borgheld JK, Andolf E. Transvaginal sonography ovarian findings in a random of women 25- 40 years old. *Ultrasound Obstet Gynecol* 1999; 13:345-50.
- 4- Osmers R, Osmers M, von Maydell B, Wagner B, Kuhn W. Preoperative evaluation of ovarian tumors in the premenopause by transvaginal sonography. *Am J Obstet Gynecol* 1996; 175:428-34.
- 5- Ammann M, Hanggi W, Baumann U, Keller PJ. Differential diagnosis of cystic ovarian tumors by determination
- 6- McLuggage WG, Patterson A, White J, Anderson NH. Immunocytochemical staining of ovarian cyst aspirates with monoclonal antibody against inhibin. *Cytopathology* 1998; 9:336-42.
- 7- Caione C, Minelli L, Angiolillo M. CA125, CA19.9,CEA, 17 beta-estradiol and progesterone in functional and benign cysts and carcinoma of the ovary. *Minerva Ginecol* 1994; 46:321-35.
- 8- Mulvany N, Ostorci A, Teng G. Evaluation of the estradiol in aspirated ovarian cystic lesion. *Acta Cytol* 1995 Jul-Aug; 39(4): 663-8.
- 9- Audra P, Dargent D, Akiki S, Lasne Y, Malvolti B, Rebaud A. Echographic guided puncture of ovarian cysts: Possibilities and limitations. *Rev Fr Gynecol Obstet.* 1991 Nov; 86(11): 672-5.

- 10- Gactje R, Popp LW. Is differentiation of benign and malignant cystic adnexal masses possible by evaluation of cysts fluids with respect to color, cytology, steroid hormones and tumor markers? *Acta Obstet Gynecol Scand* 1994 Jul; 73(6):502-7.
- 11- Simcock B, Anderson N. Diagnosis and management of simple ovarian cysts: an audit. *Australas Radiol.* 2005 Feb; 49(1):27-31.
- 12- Pascual MA, Herter L, Tressera F, Carreras O, Ubeda A, Dexeus S. Transvaginal Sonographic appearance of Functional
- 13- Allias F, Chanoz J, Blache G, Thivolet-Bejui F, Vancina S. Value of fine needle aspiration cytology in the management of ovarian and paraovarian cysts. *Diagn Cytopathol* 2000;22:70-80.
- 14- Granberg S, Wikland M, Jansson I. Macroscopic characterization of ovarian cancer and relation to the histological diagnosis: criteria to be used for ultrasound evaluation. *Gynecol Oncol* 1989; 35:139-44.
- 15- Rottem S, Levit N, Thaler I. Classification of ovarian lesions by high frequency transvaginal sonography. *J Clin Ultrasound* 1990; 18:359.
- 16- Morelli A, Bottero A, Bricchi G. Ovarian tumefaction: The advantage and limits of echo-guided needle aspiration: Our experience. *Minerva Ginecol* 1996; 48:521-6.
- 17- Granberg S, Crona N, Enk N, Hammarberg K, Wikland M. Ultrasound guided puncture of cystic ovarian tumors in the lower pelvis of young women. *J Clin Ultrasound.* 1989; 17:107.
- 18- De crespigny LC, Robinson HP, Davoren RA, Fortune D. The simple ovarian cyst: aspirate or operate? *Br. J Obstet Gynecol* 1989 Sep; 96 (9):1035-9.
- 19- Binelli C, Chretien MF, Yves G, Kanaya M, Alain D. Inhibin assays of ovarian cyst liquid obtained by needle aspiration may allow differential diagnosis between functional and organic cysts. *Eur J Obstet Gynecol Reprod Biol* 1997; 73(2): 161-5.
- 20- Dordoni D, Zaglion S, Zucca S, Favalli G. The role of sonographically guided aspiration in the clinical management of ovarian cysts. *J Ultrasound Med* 1993; 12:27-31.
- 21- Lipitz S, Seidman D, Manczer J. Recurrence rate after fluid aspiration from sonographically benign appearing ovarian cyst. *Obstet Gynecol* 1992; 37: 845-8.
- 22- Buckley CH. Is needle aspiration of ovarian cyst adequate for diagnosis? *Br J Obstet Gynecol* 1989; 96: 1035-9.
- 23- Wojak EM, Salvaggi SM. Fine needle aspiration cytology of cystic ovarian lesions. *Diagn Cytopathol* 1994; 11(1): 9-14.
- 24- Mulvany N. Aspiration cytology of ovarian cysts and cystic neoplasms. A study of 235 aspirates. *Acta Cytol* 1996; 40:911-20.
- 25- Davila R. Cytology of benign cystic uterine and adnexal masses. *Acta Cytol* 1993; 37: 385-90.

Table I : The overall accuracy of ultrasound, cytology, estradiol content and UCE triad in the diagnosis of functional and non-functional ovarian cysts .

Test	Functional	Non-functional	Total	Accuracy	p value
Histopathology	6	12	18	100 %	
Ultrasound	5	6	11	61.1 %	0.003*
Cytology	3	10	13	72.2 %	0.022*
Estradiol assay	4	11	15	83.3 %	0.11
UCE triad	5	12	17	94.4 %	0.5

* Significant difference ($p < 0.05$) is the comparison of the accuracy of each test with histopathology (gold standard).

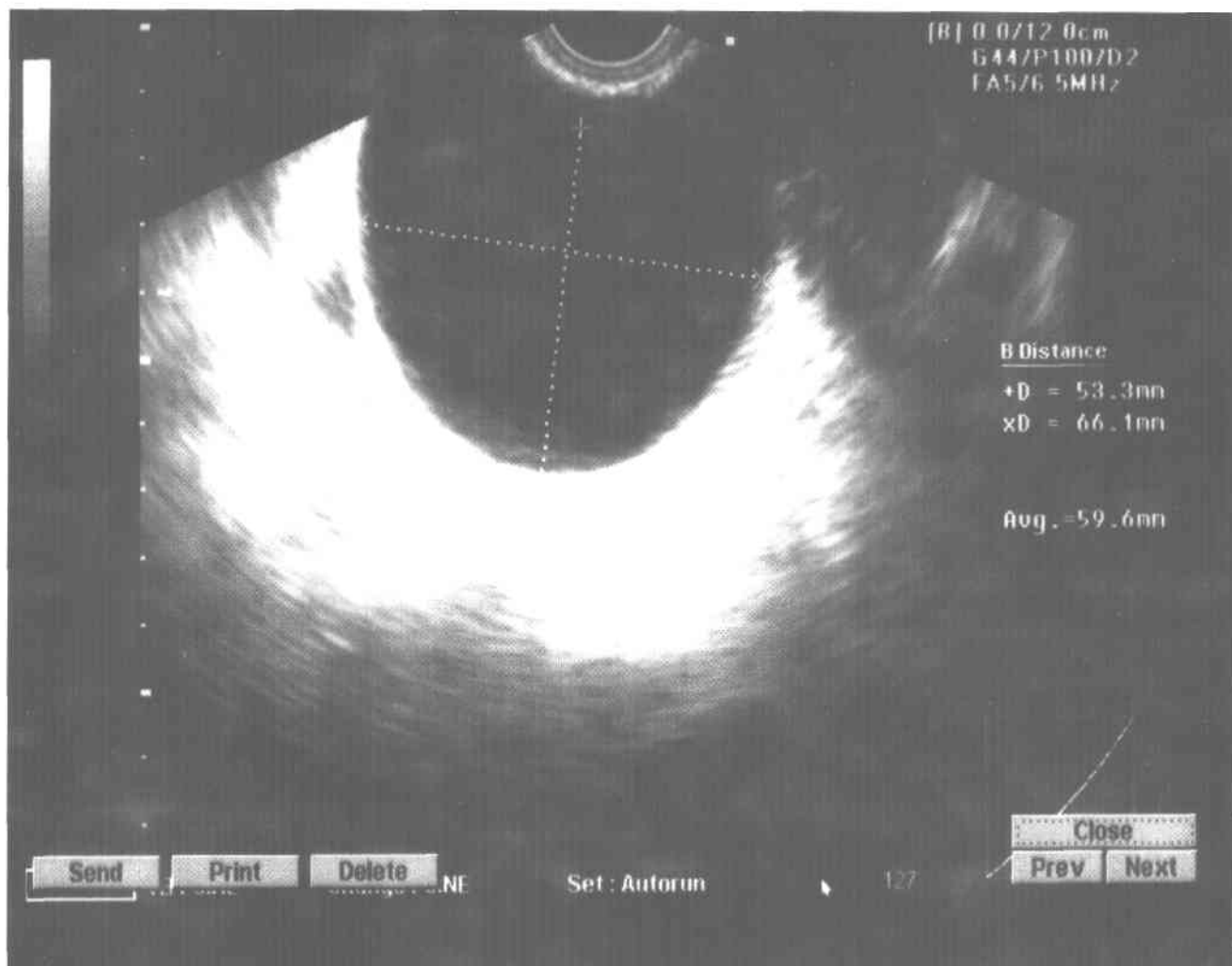


Fig. 1. Transvaginal ultrasound appearance of a functional ovarian cyst.