
Laparoscopic isthmocele repair: impact on secondary infertility after cesarean sections

Dr Mostafa Adulla Elsayed
Mahmoud
Assistant professor of obstetrics
and gynecology
Benha University

Abstract

Objective: study the effect of uterine isthmocele repair on cases with secondary infertility, abdominal pain and abnormal uterine bleeding.

Setting: Zinat Alhayat hospital in Benha from June 2019 to January 2021.

Methods: Cases recruited from those who complained from secondary infertility and delivered by cesarean section and presented with infertility and abnormal uterine bleeding in examination a lower segment cs defect was evident by vaginal ultrasound

Total number of 50 cases divided into two groups

Group one laparoscopic isthmocele repair group 25 cases (laparoscopic repair of scar defect done)

Group two controls conservative management group

Cases given chance for spontaneous pregnancy at month one

Second and third month cases given induction of ovulation with a fixed protocol of letrozole 2.5 mg twice daily from day 2 for 5 days and HMG Meriofert injection 75 u at day 3, 5, 7 of menstrual cycle.

Then follicular maturation follicular maturation was monitored with vaginal ultrasound

Primary outcome measures: pregnancy rate by the end of 3 month

Secondary outcomes: resolution of abnormal uterine bleeding and abdominal pain.

Results: regarding the total pregnancy rate at the end of the third month following surgery there were 15 pregnant cases out of 25 in the isthmoplasty group compared to 3 out of 25 in controls with p value of 0.0004 with a high statistically significant difference.

Regarding pain scores above 6 points there was one out of 25 in cases compared to 10 out of 25 in controls with p value 0.002.

Regarding abnormal uterine bleeding there were 2 out of 25 in cases compared to 12 out of 25 in controls with p value of 0.001 and a high statistical difference.

Corresponding author:

Dr Mostafa Adulla Elsayed
Mahmoud
Assistant professor of obstetrics
and gynecology
Benha University
Address: Benha kornish Elneel villa
12 street 3 CIB bank tower
01026523636
01225929020
01113382842
Emails:
Mostafaabdulla7@gmail.com
mostafaabdulla@hotmail.com
mostafaabdulla2012@gmail.com

Conclusion: cesarean scar defect repair significantly improve infertility and clinical pregnancy rate through laparoscopy.

Keywords: infertility, cesarean scar defect, isthmoplasty, clinical pregnancy rate.

Introduction

Infertility is a worldwide problem and one of the factors that increased infertility rate is the rise of cesarean section even in the absence of indication.

Endometrial receptivity can be adversely affected by large extent with presence of scar defect that creates a defect can adversely affect embryo implantation. (1)

Many factors during cesarean section procedure governs the healing pattern of the scar ,some factors like ;vicryl sutures, increasing the tension on sutures while knotting ,locking of the sutures ,leaving a lower segment small defect without repair .

Retroverted uterus also another factor, aiding in scar defect incidence due to traction on the lower segment at the level of the scar. (2)

Bad techniques during cesarean section repair can retard the healing of the lower segment leaving a defect in the isthmic region known also as isthmocele, the cesarean scar defect aka ithmocele can lead to abdominal pain, secondary infertility and abnormal uterine bleeding

Abnormal uterine bleeding in cases of cesarean scar defect occurs due to stagnation of the menstrual blood into the scar which can lead to abdominal pain and postmenstrual spotting (3,4)

Isthmocele incidence varies from 6 percent to 20 percent and become a problem in diagnosis and management that requires special attention.

Stagnation of menstrual blood in the cesarean scar defect can affect sperm transport or may even kill sperms, also retained blood can interfere with embryo implantation or may

make the developing placenta to cover the defect leading to placenta previa and accreta spectrum with an increasing morbidity and mortality.(5)

The gold standard in the diagnosis of the scar defect aka isthmocele is by transvaginal ultrasound visualization of the defect in the lower segment then confirmed by hysteroscopic visualization.

Isthmocele diagnosed as hypo-echoic defect more than 1mm and the residual myometrial thickness can be graded as 1mm or from 3-1 mm or more than 3 mm the, residual thickness governs the route of repair; when the defect is large and the residual myometrial thickness is 1mm or below that the best correction is via laparoscopic complete resection and anatomical repair. (6)

Several modalities have been implemented for the management of isthmocele one of them is hysteroscopic resection but hysteroscopic resection pregnancy rate only 30 percent this improvement with hysteroscopy can be increased by laparoscopic repair with complete excision of the defect and DE novo repair with approximations of healthy tissue. (7)

Different techniques for management varied from hysteroscopy to laparoscopy to the conservative hormonal building up with combined pills containing high estrogen.

Vaginal repair also can be done but in a blind and incomplete way so the laparoscopic approach with complete excision of the scar and total anatomical repair is the best route.

Subjects and Methods

Study design: Prospective controlled trial comparing laparoscopic repair of isthmocele to conservative management

Objectives: present work studied efficiency of laparoscopic management of cesarean scar defect in infertile patients

Setting: laparoscopic ithmoplasty done in zinat al-Hayat hospital in Benha

Primary outcome measure; pregnancy rate

Secondary outcome measures: abdominal pain, abnormal uterine bleeding.

Sample size: 50 cases

Groups

Group one: laparoscopic ithmoplasty 25 cases

Group two: conservative ithmocele observations 25

Patients recruited from private jam clinic who complained from secondary infertility after cesarean section.

Studied subject evaluations

History: complete history of the duration of infertility, age, no of living children .the place of previous cesarean section and all details about previous sections including duration of the operation, antepartum or postpartum bleeding any blood transfusion

Complete examination general abdominal examination done

Investigations laboratory

CBC

Fasting blood sugar

TSH, t3, t4

Antinuclear antibody

Vitamin D3

Calcium

Liver function test SGPT, SGOT, bilirubin

Kidney function test urea and creatinine

Assessment of abdominal pain was done by visual analogue scale of pain and all participants given a card numerated from 0 to 10 to score the pain

Tran-vaginal scan at first visit

Thorough pelvic organ evaluation

Assessment of the ovarian volume antral follicle count and ovarian stromal flow indices

Assessment of Douglas pouch and utero-sacral ligaments

Uterine evaluation: with trans-vaginal examination after emptying bladder using sonoscape p25 (china) mid-sagittal view to visualize the site of the scar and noticing hypo-echoic defects with measurement of the residual myometrial thickness to categorize the defect

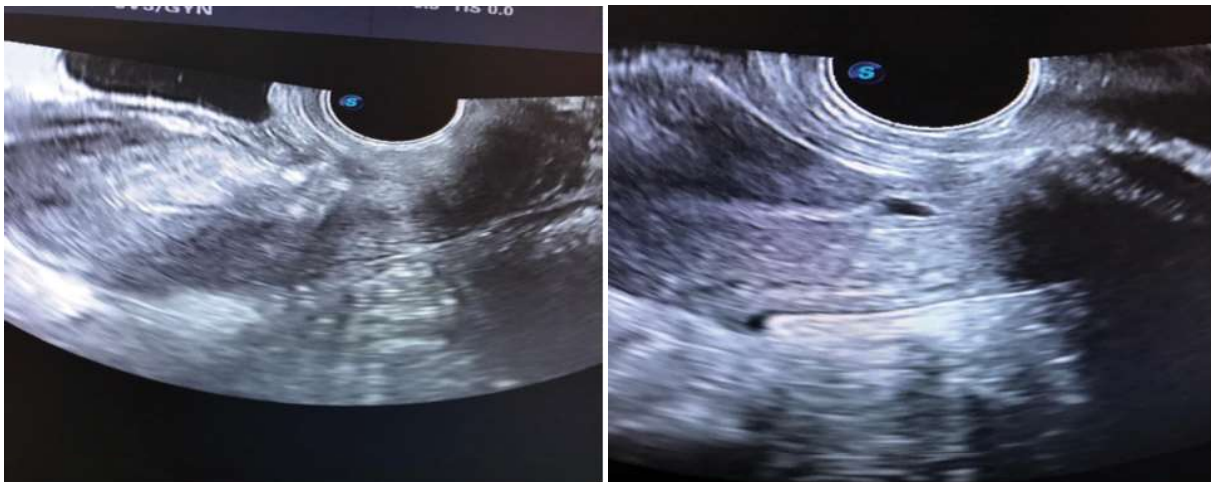

Figure 1 the ultrasound evaluation pf the scar defect before and after ithmoplasty

Standard semen analysis and it is my routine to do computer assisted semen analysis and hystero-salpingeogram done to assess tubal patency and exclude other causes

Reevaluation by ultrasound done after isthmoplasty to confirm anatomical restoration and closure of the defect

The repair

Cases with confirmed scar defect scheduled for laparoscopic isthmoplasty in Zinat al-Hayat hospital with complete preoperative assessment with examination and full laboratory investigations then after overnight fast all surgeries done in the early morning through laparoscopy combined with hysteroscopy

First hysteroscopic evaluation with telescopic sheath to visualize the tubal ostia, the endometrium, and confirming the site location and extent of the defect

Following hysteroscopic localization of the defect and evaluation of the whole uterine cavity done to ensure absence of the causes of infertility and bleeding

Laparoscopy then done and it was my routine to make the optical port two finger breadth above the umbilicus to avoid injuries of anticipated adhesions with intestine.

The two other ports inserted one for atraumatic grasper and the other for ligasure.

Thorough pelvic exploration done.

Exploration of the upper abdomen.

Most of the cases had adhesions between the scar and the anterior abdominal wall .

Adhesions cut

Uterovesical peritoneum is grasped with atraumatic grasper and traction made to aid in easy cutting and coagulation with ligasure device

After cutting bladder reflection, dissection done with ligasure until complete exploration of the area of the scar, and this dissection of bladder flap protects bladder from accidental injuries.

The scar area perforated with a hook then debridement and excision of the entire old scar done with scissor and Maryland artery

The scar is closed carefully with Vicryl (polyglactin) absorbable sutures by needle holders with complete security of bleeding points

Final irrigation done

Complete exploration of the repaired site done to secure hemostasis.

Postoperative follow up and treatment

First month

Cases and controls left without induction but ovulation monitored by trans-vaginal ultrasound sonoscape p25

The cases monitored by ultrasound after repair to compare the picture before and after the repair

If there was a missed period pregnancy test done

Second and third month

Cases and controls induced for ovulation with Letrozole (Femara) 2.5 mg from the second day twice daily for 5 days then HMG Meriofert (IBSA) 75 unit given IM at the 3th, 5th, and 7th day of menstrual cycle

Growing follicles monitored with vaginal ultrasound and when at least one follicle reached 18-20 mm ovulation was triggered.

Ovulation triggered with 250 µg recombinant human chorionadotropin (Ovitrelle, Serono, Madrid, Spain)

Chemical pregnancy diagnosed after 14 days with quantitative HCG and when pregnancy confirmed pregnancy followed by ultrasound until fetal viability of clinical pregnancy reached

Statistics

All tests were two tailed with a confidence level of 95% ($p < 0.05$).

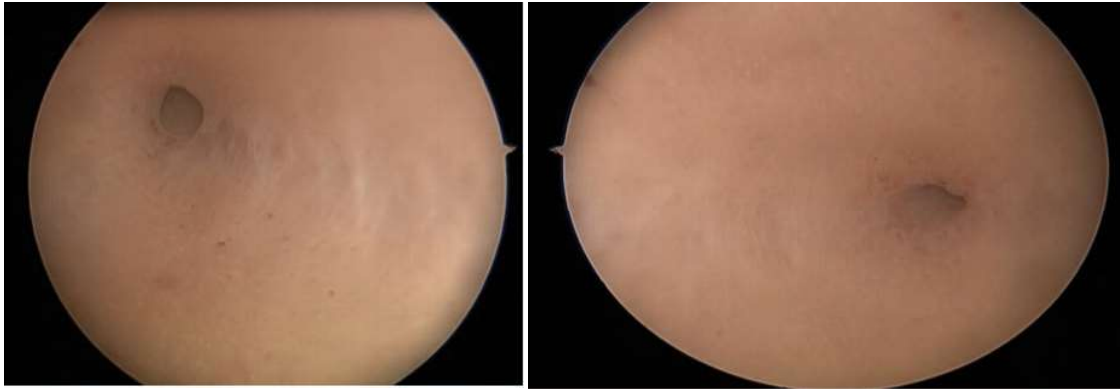
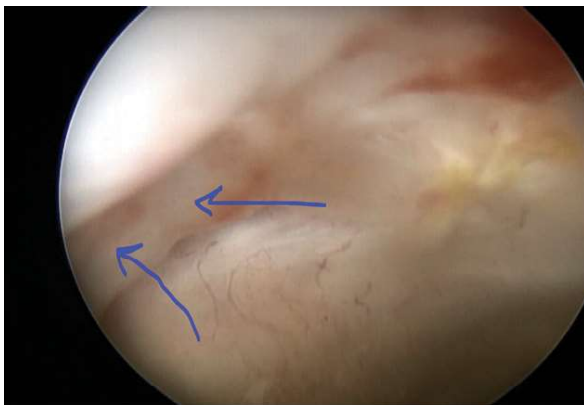
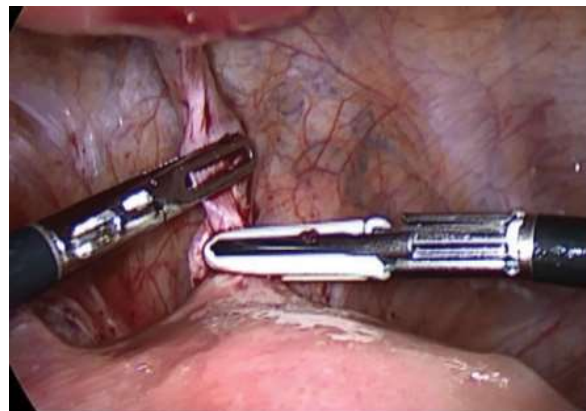
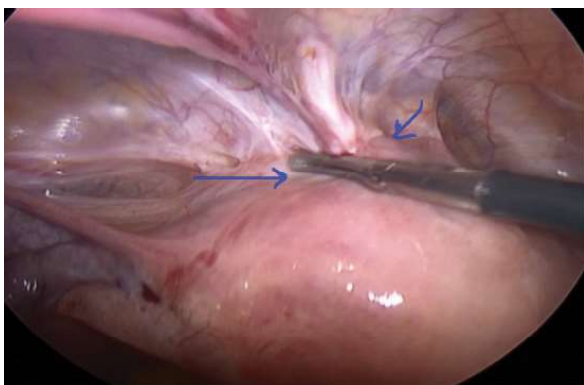
Figure2 two hysteroscopic views of both tubal Ostia sides before correction



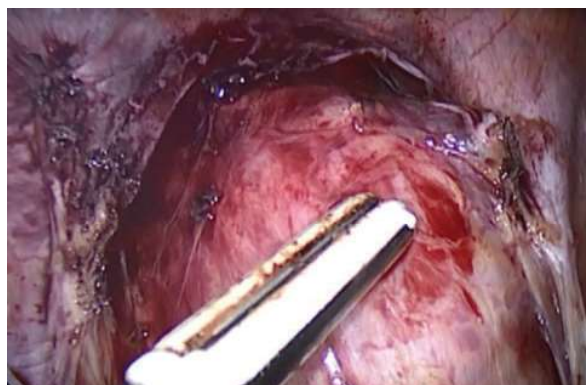(Figure 3) Hysteroscopic localization of the scar defect arrows show the defect in muscle layer



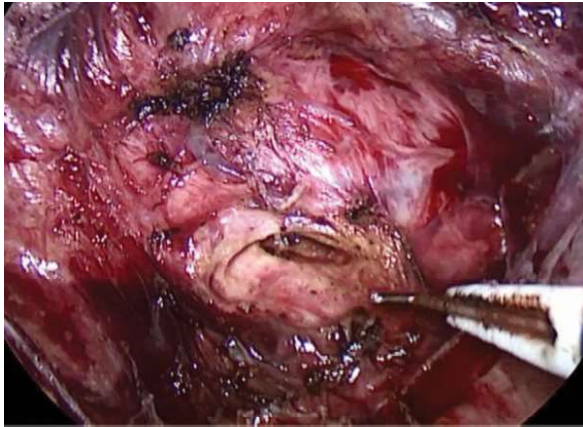(Figure 5) Fixing peritoneal fold covering the adhesion with atraumatic grasper and cutting with ligasure



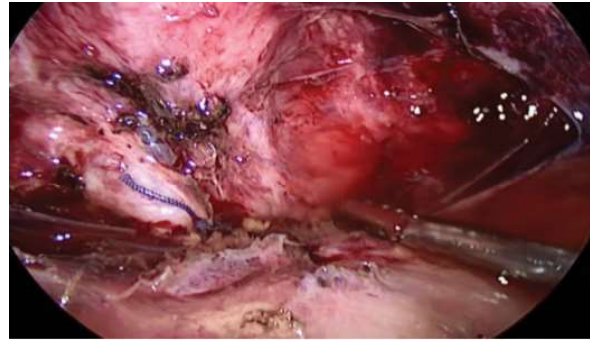
(Figure4) shows laparoscopic view of the scar site with dense adhesions between the scar and the anterior abdominal wall



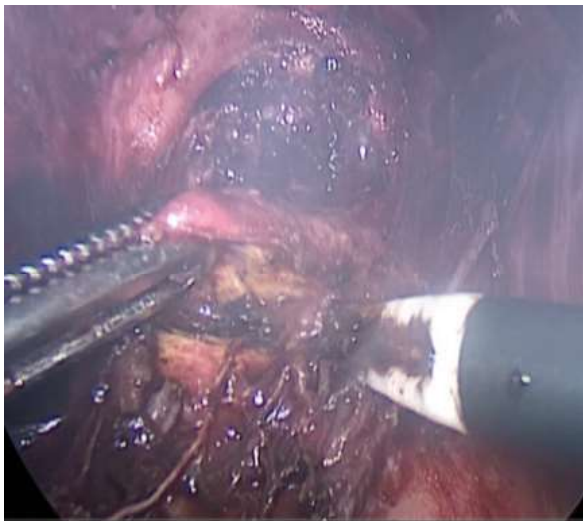
(Figure 6) Complete dissection of utero-vesical peritoneal reflection with exposure of the area of scar defect



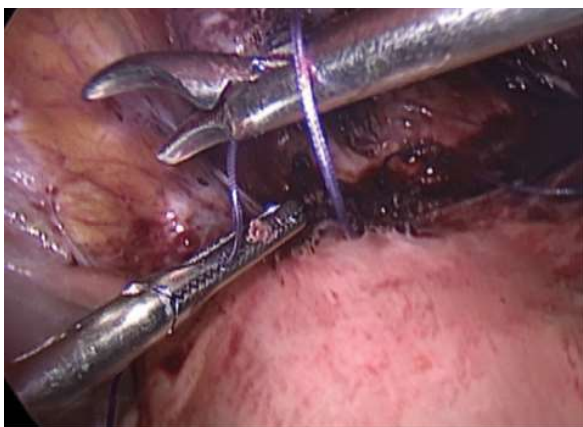(Figure 7) The scar exposed and muscle of the scar was perforated using a hook



Final wound irrigation



(Figure8) scar defect incised and cut



(figure9) The scar was sutured with absorbable sutures

Results

First item evaluated with all participants was pain scores after doing the isthmoplasty ,regarding pain scores there were one case out of 25 compared to 10 cases out of 25 in the control that showed a high pain score above 6 with p value of 0.002 a high statistically significant difference

Regarding abnormal uterine bleeding after surgery there were only 2 cases out of 25 compared to 12 cases in the controls that showed abnormal bleeding with p value of 0.001

Regarding pregnancy in the first month of monitoring after surgery there were 5 out of 25 in the ithmoplasty group compared to 1 out of 25 in controls that showed pregnancy with p value of 0.08 a non-significant difference

Regarding pregnancy in the second and third months following isthmoplasty there were a pregnancy rate of 10 out of 25 compared to 2 out of 25 in controls with p value of 0.008 a high statistically significant difference that signified the success of scar surgery

The total pregnancy rate in cases was 15 out of 25 compared to 3 in controls with P value of 0.0004 a high statistically significant difference. Table 1

Table 1 major and minor outcome measures after isthmoplasty

item	Group one laparoscopic isthmocele repair	Group two conservative management group	P value
Abdominal pain score more than 6	1 out of 25	10 out of 25	0.002
Abnormal uterine bleeding post menstrual	2	12 out of 25	0.001
Pregnancy in the first month	5 out of 25	1 out of 25	0.08
Pregnancy in the second and third month	10	2	0.008
Total pregnancy rate	15	3	0.0004

Discussion

Cesarean section is a daily practice for every obstetrician, there is a rising level of non-indicated cesarean section worldwide.

High rate of cesarean sections have its own complications including placenta previa and accrete spectrum, also the new era of scar defect known by the name of uterine niche.

uterine niche or the cesarean scar defect can lead to abnormal uterine bleeding due to the accumulation of menstrual blood in the defect leading to postmenstrual spotting ,also the raw area of the scar subjected every month to the effect of menstrual blood that erodes the defect more and this ulceration add a negative impact and increase the inter-menstrual spotting.

Uterine niche can also cause infertility through impairment of implantation by continuous dripping of stagnated blood at the endometrial implantation site, uterine niche also has a negative hostile effect on sperms and sperm transport. (8)

Regional inflammatory effect around the scar defect can hinder implantation and lead to chronic endometritis with chronic pelvic pain. (9)

Scar defect us diagnosed efficiently with trans-vaginal ultrasound and diagnosis confirmed through hysteroscopy.

The presented work studied the repair effect of isthmocele on the pregnancy rate in infertile patients

Cases with diagnosed scar defect and secondary infertility scheduled for laparoscopic repair called laparoscopic isthmoplasty.

In the presented work total pregnancy rate was 15 out of 25 in cases done with laparoscopy compared to 3 out of 25 in controls with p value of 0.0004 which signified the high positive impact .

Regarding abnormal uterine bleeding there were 2 out of 25 in cases compared to 12 out of 25 in controls complained of postmenstrual spotting with p value of 0.001 and a high statistically significant difference.

The presented work studied the surgical repair of scar defect aka (ithmoplasty) impact on pregnancy rate.

Hysteroscopic repair of cesarean scar defect may have certain complications like uterine perforation and bladder injuries.

Cesarean scar defect can be categorized by ultrasound into three classes according to the residual muscle wall thickness, when the residual myometrial thickness below 2.5 mm the risk of bladder injury during hysteroscopic repair is high.

Donney et al performed laparoscopic repair when residual myometrial thickness below 3 mm. (10)

Gubbini performed hysteroscopic isthmoplasty for 41 patients all of them achieved spontaneous pregnancy but his results need further evaluation because nothing in the universe is absolute. (11)

Conflict of interest

No conflicts of interest to declare.

References

1. Tulandi T, Cohen A. Emerging manifestations of cesarean scar defect in reproductive-aged women. *J Minim Invasive Gynecol.* 2016; 23(6): 893– 902.
2. Nezhat CM, Grace L, Soliemannjad R, Razavi GM, Nezhat A. Cesarean scar defect: what is it and how should it be treated? *Obg Manag.* 2016; 28(4): 32– 53.
3. Abacjew-Chmylko A, Wydra DG, Olszewska H. Hysteroscopy in the treatment of uterine cesarean section scar diverticulum: a systematic review. *Adv Med Sci.* 2017; 62(2): 230– 9.
4. Kremer TG, Ghiorzi IB, Dibi RP. Isthmocele: an overview of diagnosis and treatment. *Rev Assoc Med Bras (1992).* 2019; 65(5): 714– 21.
5. Muzii L, Domenici L, Lecce F, Di Feliciano M, Frantellizzi R, Marchetti C, et al. Clinical outcomes after resectoscopic treatment of cesarean-induced isthmocele: a prospective case-control study. *Eur Rev Med Pharmacol Sci.* 2017; 21(15): 3341– 6.
6. Maeda E, Ishihara O, Tomio J, Sato A, Terada Y, Kobayashi Y, et al. Cesarean section rates and local resources for perinatal care in Japan: a nationwide ecological study using the national database of health insurance claims. *J Obstet Gynaecol Res.* 2018; 44(2): 208– 16.
7. van der Voet LF, Bij de Vaate AM, Veersema S, Brölmann HA, Huirne JA. Long-term complications of caesarean section. The niche in the scar: a prospective cohort study on niche prevalence and its relation to abnormal uterine bleeding. *BJOG.* 2014; 121(2): 236– 44.
8. Florio P, Filippeschi M, Moncini I, Marra E, Franchini M, Gubbini G. Hysteroscopic treatment of the cesarean-induced isthmocele in restoring infertility. *Curr Opin Obstet Gynecol.* 2012; 24(3): 180– 6.
9. Vervoort AJ, Uittenbogaard LB, Hehenkamp WJ, Brölmann HA, Mol BW, Huirne JA. Why do niches develop in caesarean uterine scars? Hypotheses on the aetiology of niche development. *Hum Reprod.* 2015; 30(12): 2695– 702.
10. Donnez O. Cesarean scar defects: management of an iatrogenic pathology whose prevalence has dramatically increased. *Fertil Steril.* 2020; 113(4): 704– 16.
11. Gubbini G, Casadio P, Marra E. Resectoscopic correction of the "isthmocele" in women with postmenstrual abnormal uterine bleeding and secondary infertility. *J Minim Invasive Gynecol.* 2008; 15(2): 172– 5.